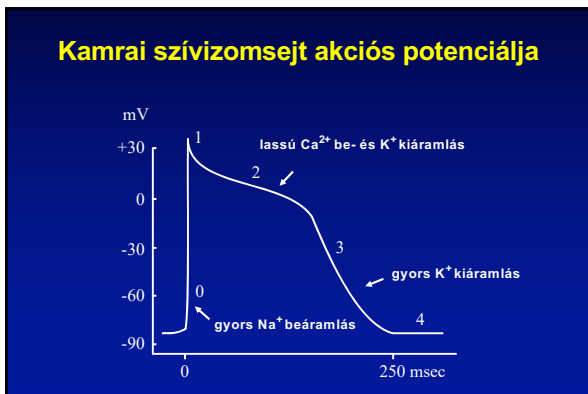


AZ EKG ALAPJAI

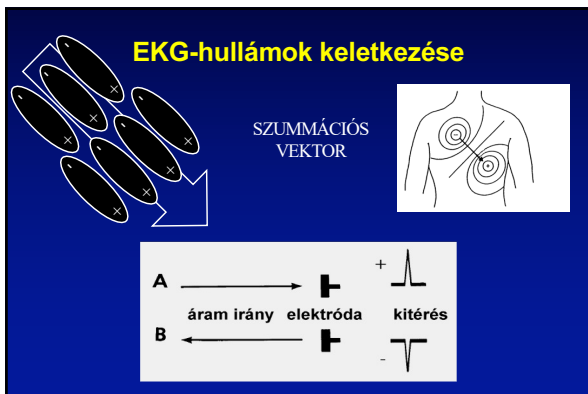DEBRECENI EGYETEM
ÁLTALÁNOS ORVOSTUDOMÁNYI KAR
KLINIKAI FIZIOLÓGIAI TANSZÉK



1

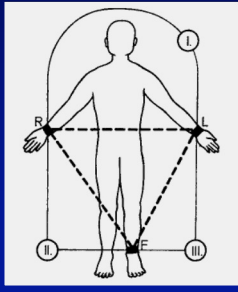


2



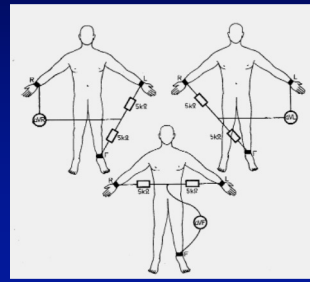
3

Standard végtagi elvezetések



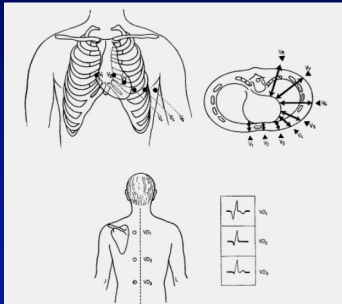
4

Goldberger-féle unipoláris elvezetések

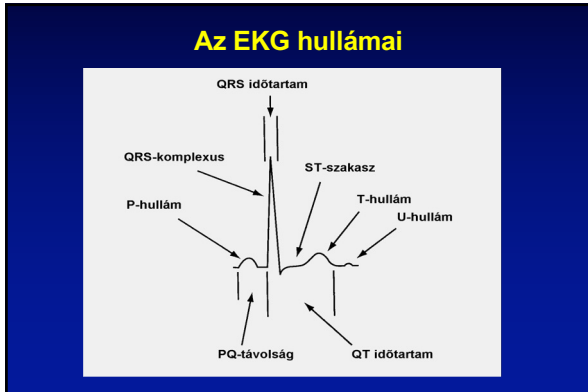


5

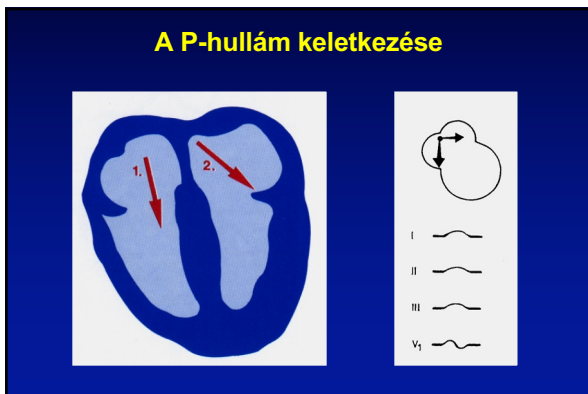
Mellkasi- és dorsalis elvezetések



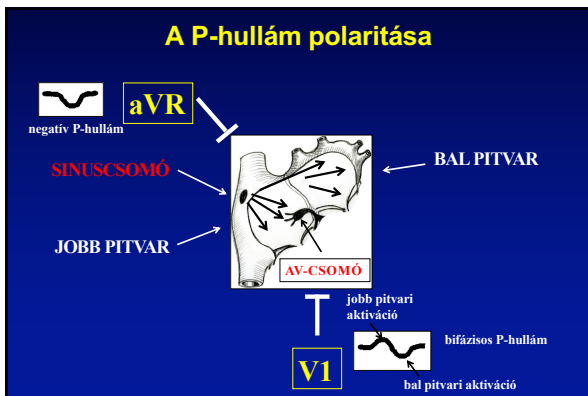
6



7

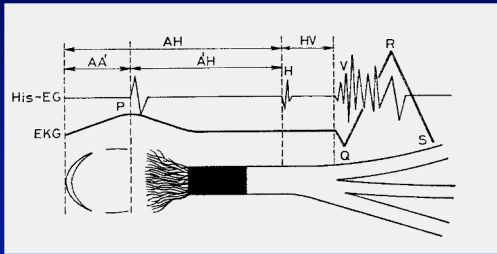


8



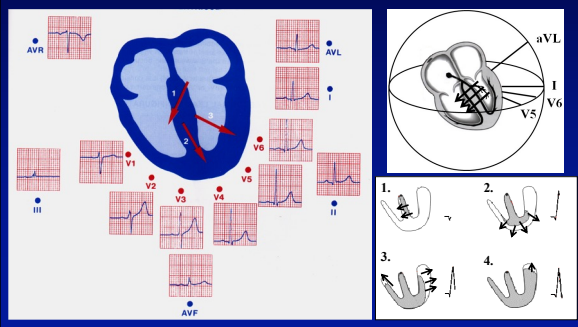
9

His-nyaláb elektrogram



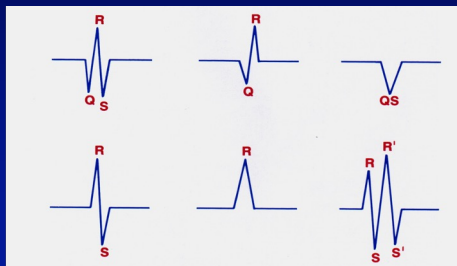
10

A kamrai aktiváció fázisai



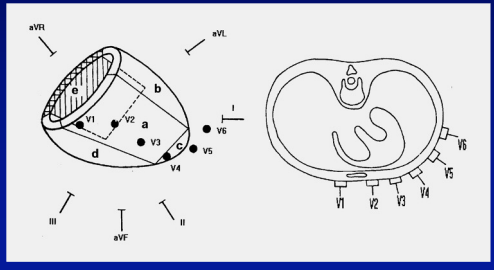
11

QRS-komplexus nomenklatúra



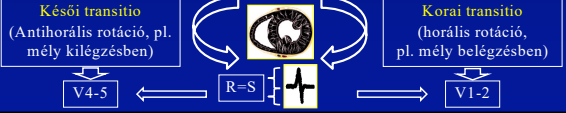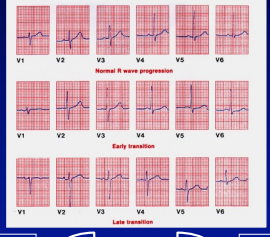
12

Az EKG elvezetések orientációja



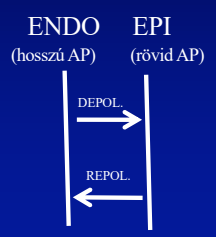
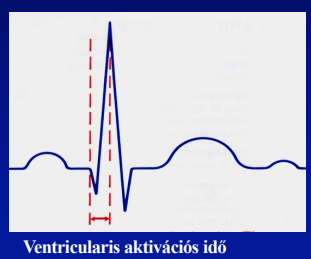
13

Mellkasi elvezetések, R- hullám progresszió



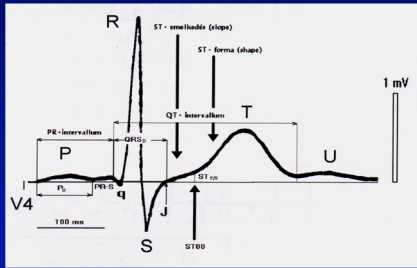
14

Ventricularis aktivációs idő (VAT)



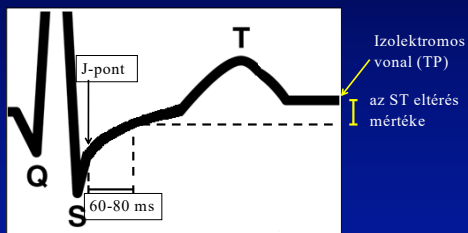
15

ST-szakasz, T- és U-hullám



16

ST-szakasz

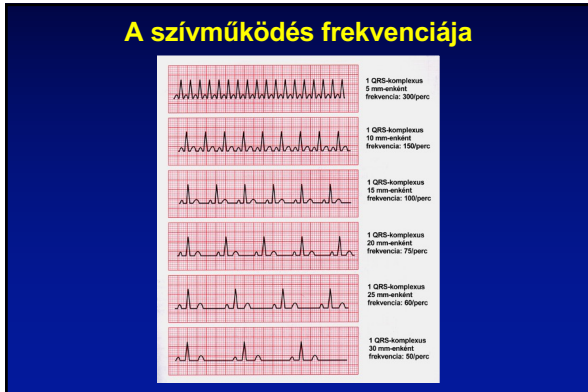

17

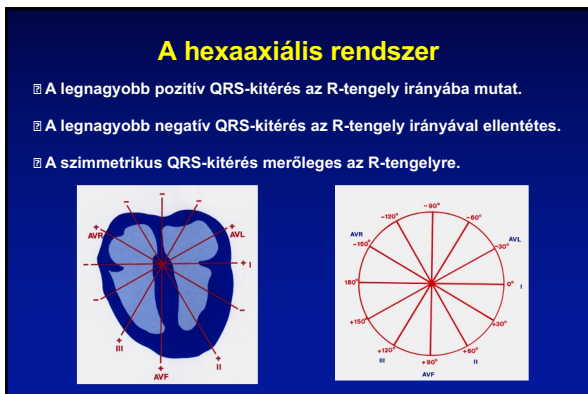
Az EKG-értékelés szempontjai

1. Alapritmus
2. Frekvencia
3. R-tengelyállás
4. P-, PQ-, QRS-, ST-, QT-idők
5. Hullámok morfológiája
6. Vélemény

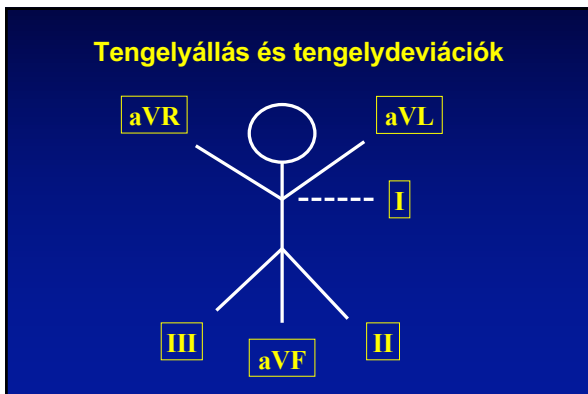
18



19

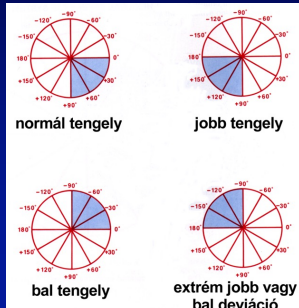


20

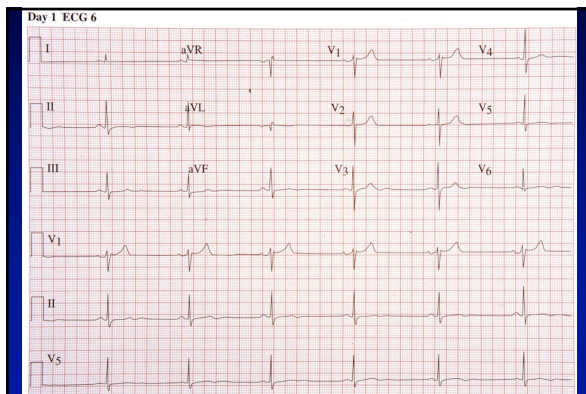

21

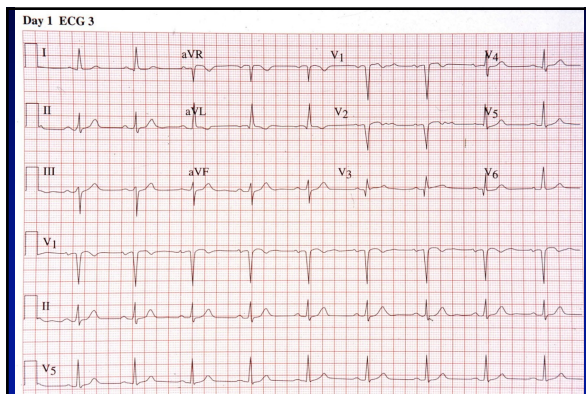
Tengelyállás és tengelydeviációk



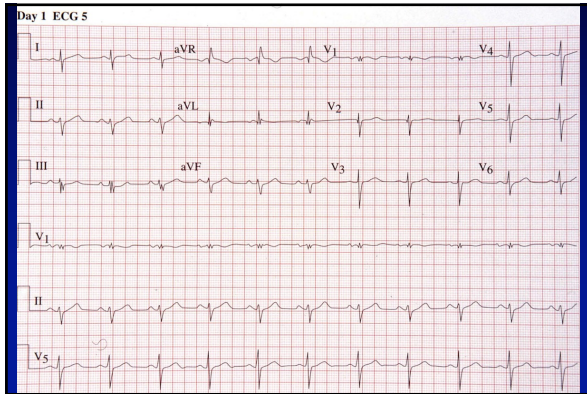
22



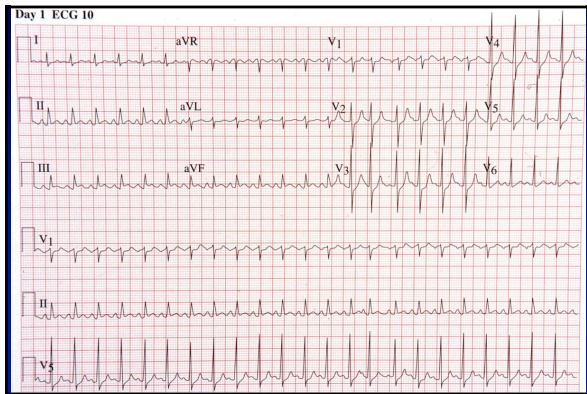
23



24



25



26



27
